



Modified Cricothyroidotomy in Skill Laboratory

Hassan Soleimanpour^{1*}, Samad Shams Vahdati¹, Ata Mahmoodpoor², Jafar Rahimi Panahi²,
Mohammad Reza Afhami², Mahboub Pouraghaei¹, Samad EJ Golzari^{3,4}

¹Department of Emergency Medicine, Tabriz University of Medical Sciences, Tabriz, Iran

²Department of Anesthesiology, Tabriz University of Medical Sciences, Tabriz, Iran

³Physical Medicine and Rehabilitation Research Center, Tabriz University of Medical Sciences, Tabriz, Iran

⁴Students Research Committee, Tabriz University of Medical Sciences, Tabriz, Iran

ARTICLE INFO

Article Type:

Research Article

Article History:

Received: 2 June 2012

Accepted: 8 Aug 2012

ePublished: 23 Sep 2012

Keywords:

Percutaneous Cricothyroidotomy
Difficult Airway Management
Skill Laboratory

ABSTRACT

Introduction: Unsuccessful tracheal intubation is considered the most common cause of anesthesia death or brain damage. This study delineates our experience recommending modifications in the cricothyroidotomy technique. **Methods:** Thirty emergency medicine residents participated in a study performed on the human simulator moulage in Skill Laboratory of Tabriz University of Medical Science. The cricothyroid membrane was punctured using a 16-gauge cannula. Later, J guide wire was advanced into trachea and standard 16-gauge intravenous cannula with a removable needle stylet withdrawn after the puncture being dilated by a dilator. Consequently, a cuffed tracheal tube (ID= 6) was introduced from the foramen. **Results:** From 30 residents, 18 residents performed cricothyroidotomy within 1 minute, 7 residents in 2 minutes and 5 residents failed to fulfill the procedure. **Conclusion:** Several studies using cadavers and human simulators have demonstrated the pre-hospital feasibility of this technique. However, descriptions of clinical pre-hospital experience with percutaneous cricothyroidotomy are limited. This study shows that skill lab may help residents to acquire techniques required in management of difficult airway.

Introduction

From the point of view of medical directors, adequate training in the use of efficient and available alternate airways is essential.¹⁻³ Maintenance of alternate airway skills is of great importance due to their clinical use occurring under urgent conditions.^{3,4} Both simulated and practical experiences are required for training these skills.⁵⁻⁷

Training on live patients in controlled settings seems quite desirable; however, for most alternate airways in emergency conditions, this may not be practical. For instance, elective cricothyroidotomy rarely occurs on the operating room patients.⁷

Although, no clinical indications for alternate airway use have been defined, it is practically recommended for the alternate airways to be used following failed endotracheal intubation (ETI) attempts or in situations where endotracheal intubation attempts seem to be difficult or impossible. "Difficult Airway" is defined as conditions involving difficult airway anatomy, severe airway trauma, or inadequate operator skill. This could be identified before or after initial intubations attempts. In situations where airway management difficulty is obviously beyond the skill of the operator, it is recommended to consider alternate airway management.^{8,9}

Difficult airway guidelines recommend only three intubation attempts (insertion of blade) and any further endotracheal intubation efforts should be discontinued.^{8,9} Alternate airway use should be monitored by a comprehensive quality assurance and quality improvement programs involving emergent medical directors in continuous quality improvement (CQI) activities. All usage of alternate and salvage airways should be documented based on "Recommended Guidelines for Uniform Reporting of Data from Pre-hospital Airway Management".¹⁰

It is highly recommended to maintain patient follow-up including linkage to in-hospital course as the only indicators of pre-hospital difficult airway management complications.

Percutaneous cricothyroidotomy, first described as an in-hospital alternate airway by Fischer, has been proposed in the anesthesia literature for difficult airway management.⁷ Problems with tracheal intubation in spite of being infrequent are the most common cause of anesthesia death or brain damage.

We hypothesized that percutaneous dilatational cricothyroidotomy might be performed in the failed or difficult airway as an alternative as it seems to be simpler than other alternatives.

*Corresponding author: Hassan Soleimanpour, E-mail: soleimanpourh@tbzmed.ac.ir

Materials and methods

Study Design

This study was a randomized controlled cross-over design on human simulator moulage which was performed for the first time in Tabriz University of Medical Science, Iran.

Study Setting

This study was held in skill lab of educational development center (EDC) of Tabriz Medical University. Residents of emergency medicine participated in this study.

Methodology of Study

The disposable percutaneous introducer kit consists of a standard 16-gauge intravenous cannula with a removable needle stylet (No- 16 blade), a translucent syringe, a J-tipped 0.052 inch coated stainless steel guide wire, an introducing dilator and lubricating gel.

STEP 1(Localization and perforation): Skin perforation was performed at the lower edge of the thyroid cartilage in cricothyroid cartilage. The trachea was punctured using a standard 16-gauge intravenous cannula with a removable needle stylet; as the needle was advanced into the tracheal lumen air was aspirated with the syringe.

STEP 2(Insertion of J wire): The needle was pulled back and the J tipped guide wire advanced into the tracheal lumen.

STEP 3(Incision and Dilation): Cricothyroid membrane was incised minimally and vertically in both sides of J wire insertion for the purpose of dilator insertion facility. The dilator was mounted on the guide wire.

STEP 4[Cuffed tracheal tube (ID= 6)]: In this step, the dilator was withdrawn and cuffed tracheal tube was inserted (ID= 6) through the foramen; later J guide wire was extracted. Finally, tracheal tube was fixed in place with tape.

STEP 5(Confirmation): Tracheal tube position was checked by symmetrical chest rising and auscultation.

Data

The number of the attempts were recorded at the end of first minute, second minute and if failed after 2 minutes. The obtained data were compared between these residents.

Data analysis

The data were analyzed in SPSS 15.0 statistical package and descriptive analysis was performed for all data.

Results

Thirty emergency medicine residents worked on the same kind of human simulator moulage and the start and the finishing times of the procedure were documented for all of them. Eighteen residents finished the procedure within the first minute, 7 residents in second minute and 5 residents failed to perform the procedure (Figure 1). The mean time of procedure completion was 84.8 ± 52.6 seconds (Median=59 seconds and Mode=58 seconds; Figure 2).

Primary outcome was defined as successful cannulation; 3

of the participants failed this step requiring more time for fulfilling the procedure. Secondary outcome included needle insertion which was performed successfully by all of the participants. Final proportion was successful intratracheal insertion and subjective ease of insertion. Two of participants failed and could not perform the procedure properly.

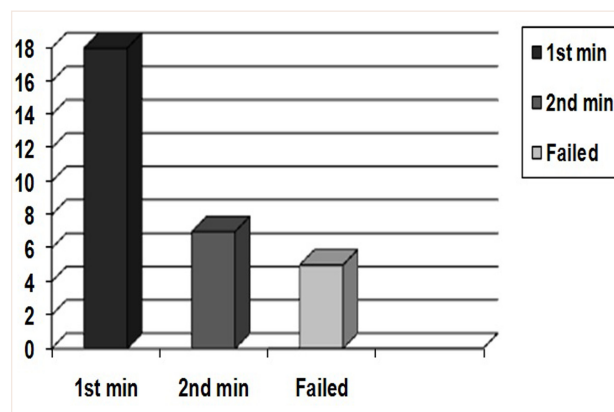


Figure 1. The procedure completion in 1st and 2nd minutes (people)

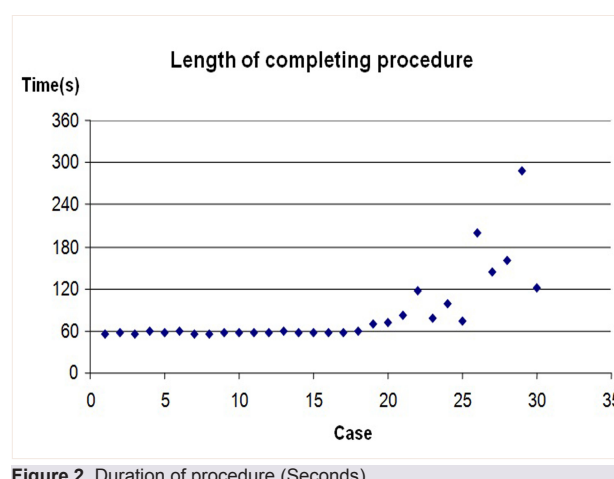


Figure 2. Duration of procedure (Seconds)

Discussion

Being used for over 45 years^{11,12}, open cricothyroidotomy is a safe and rapid procedure; however, it does require appropriate training.¹³⁻¹⁶ Cricothyroidotomy has been studied in the hospital and emergency department settings as both a primary and alternate airways for management of difficult airway.^{17,18} Several trials have described cricothyroidotomy use in the pre-hospital settings.^{16,19} In spite of being widely taught, the pre-hospital application of cricothyroidotomy has been reported to be rare and blamed for having significant complications and poor outcomes.^{11,16,20,21}

Some of the indications for cricothyroidotomy include oral and maxillofacial trauma, suspected cervical spine injury, and inability to perform endotracheal intubation because of oral hemorrhage, emesis, or anatomy that obscures visualization of the vocal cords. Cricothyroidotomy seems to be relatively easy (relative to a tracheotomy) to perform

for non-physicians or non-surgeons in the emergency surgical airway access while minimal training is required.

Laryngeal pathology remains the solely most important contraindication for cricothyroidotomy. Conditions causing inflammation are its contraindications including trauma, infection, and translaryngeal intubation.²²

Percutaneous cricothyroidotomy uses a modified Seldinger (guide wire) technique to facilitate location and insertion of a tracheal tube through the cricothyroid membrane. Commercially packaged kits contain the equipment necessary to perform the procedure.^{23-29,33} Being first described as an in-hospital alternate airway by Fischer³⁴, percutaneous cricothyroidotomy technique is believed to have fewer complications than open cricothyroidotomy.³⁰⁻³² Percutaneous cricothyroidotomy has been described in the anesthesia literature for difficult airway management.^{34,35} It was not until 1992 that the use of percutaneous cricothyroidotomy was first described in the emergency department.³⁶ The pre-hospital use of percutaneous cricothyroidotomy was proposed over a decade ago.³⁶ Several studies using cadavers and human simulators have demonstrated the pre-hospital feasibility of this technique.^{30,31,37} However, very limited descriptions of clinical pre-hospital experience with percutaneous cricothyroidotomy could be found.

Schumann *et al.* believed that it is important to train residents with different methods of cricothyroidotomy in cadavers in addition to training in mannequins to achieve a higher level of efficacy in real-life situations.³³ Metterlein *et al.* showed that wire-guided method is a more reliable technique, being associated with fewer complications. However, the direct puncture was faster to perform. Whenever placed accurately, both devices would provide sufficient ventilation.³⁸ Aneeshkumar *et al.* reported that with adequate prior training, it is a quick, simple and safe procedure, resulting in no significant cardio-respiratory complications and providing efficient ventilation in emergency situations.³⁹ In our study, we observed that this procedure could be performed in emergency states so easily and quickly.

Ciaglia *et al.* showed that percutaneous dilatational method can be used with safety and speed.³⁷

Conclusion

In summary, several studies using cadavers and human simulators have demonstrated the pre-hospital feasibility of this technique. Descriptions of clinical pre-hospital experience with percutaneous cricothyroidotomy are limited, however this study shows that this method might be considered as a new and simple way to overcome difficult airway in emergent situations.

Ethical issues: The local ethics committee of Tabriz University of Medical Sciences approved the study and all patients signed informed consent.
Conflict of interests: The authors declare no conflicts of interest.

References

1. Soleimanpour H, Gholipouri C, Panahi JR, Afhami MR,

Ghafouri RR, Golzari SE, et al. Role of anesthesiology curriculum in improving bag-mask ventilation and intubation success rates of emergency medicine residents: a prospective descriptive study. **BMC Emerg Med** 2011; 11:8.

2. Soleimanpour H, Sarahrudi K, Hadju S, Golzari SEJ. How to Overcome Difficult-Bag-Mask-Ventilation: Recent Approaches. **Emergency Medicine** 2012; 2:e116.

3. Soleimanpour H, Panahi JR, Mahmoodpoor A, Ghafouri RR. Digital intubation training in residency program, as an alternative method in airway management. **Pak J Med Sci** 2011;27:401-4.

4. Soleimanpour H, Khoshnudi F, Movaghar MHS, Ziapour B. Improvement of decerebrate status in a hanged child following emergent tracheostomy. **Pak J Biol Sci** 2010; 13: 1164-5.

5. Schaefer JJ 3rd. Simulators and difficult airway management skills. **Paediatr Anaesth** 2004; 14:28-37.

6. Berridge PD, Pollock KM, Longhorn RK, Heard AM. Emergency airway equipment and training. **Anaesthesia** 2005; 60:291-2.

7. Zirkle M, Blum R, Raemer DB, Healy G, Roberson DW. Teaching emergency airway management using medical simulation: a pilot program. **Laryngoscope** 2005; 115:495-500.

8. Wang HE, Kupas DF, Greenwood MJ, Pinchall ME, Mullins T, Gluckman W, et al. An algorithmic approach to prehospital airway management. **Prehosp Emerg Care** 2005; 9:145-55.

9. Wang HE, Yealy DM. How many attempts are required to accomplish out-of-hospital endotracheal intubation? **Acad Emerg Med** 2006; 13:372-7.

10. Wang HE, Domeier RM, Kupas DF, Greenwood MJ, O'Connor RE. Recommended guidelines for uniform reporting of data from out-of-hospital airway management: position statement of the National Association of EMS Physicians. **Prehosp Emerg Care** 2004;8:58-72.

11. Xeropotamos NS, Coats TJ, Wilson AW. Pre-hospital surgical airway management: 1 years experience from the Helicopter Emergency Medical Service. **Injury** 1993;24:222-4.

12. Nelson TG, Rumer GF, Nicholas TH. Cricothyroidotomy in complete airway obstruction. **Am J Nurs** 1961;61:74-6.

13. Wong DT, Prabhu AJ, Coloma M, Imasogie N, Chung FF. What is the minimum training required for successful cricothyroidotomy?: a study in mannequins. **Anesthesiology** 2003; 98:349-53.

14. Chang RS, Hamilton RJ, Carter WA. Declining rate of cricothyrotomy in trauma patients with an emergency medicine residency: implications for skills training. **Acad Emerg Med** 1998; 5:247-51.

15. O'Connor D, Longhorn R, Heard A. Emergency surgical airway training in Western Australia. **Anaesthesia** 2004; 59:919.

16. Salvino CK, Dries D, Gamelli R, Murphy-Macabobby M, Marshall W. Emergency cricothyroidotomy in trauma victims. **J Trauma** 1993; 34:503-5.

17. Bair AE, Panacek EA, Wisner DH, Bales R, Sakles JC. Cricothyrotomy: a 5-year experience at one institution. **J Emerg Med** 2003; 24:151-6.

18. Jones I, Roberts K. Towards evidence based emergency medicine: best BETs from the Manchester Royal Infirmary. To stab or slash: the percutaneous dilatation or standard surgical approach to cricothyroidotomy in pre-hospital care. **Emerg Med J** 2002; 19:434.

19. Granholm T, Farmer DL. The surgical airway. **Respir Care Clin N Am** 2001; 7:13-23.
20. Bulger EM, Copass MK, Maier RV, Larsen J, Knowles J, Jurkovich GJ. An analysis of advanced pre-hospital airway management. **J Emerg Med** 2002; 23:183-9.
21. Fortune JB, Judkins DG, Scanzaroli D, McLeod KB, Johnson SB. Efficacy of prehospital surgical cricothyrotomy in trauma patients. **J Trauma** 1997; 42:832-6.
22. Cole RR, Aguilar EA. Cricothyroidotomy versus tracheotomy: An otolaryngologist's perspective. **Laryngoscope** 1988; 8:131-5.
23. Guyette FX, Greenwood MJ, Neubecker D, Roth R, Wang HE. Alternate airways in the prehospital setting (resource document to naemsp position statement). **J Trauma** 1997;42:832-8.
24. Galloway TC. Tracheotomy in bulbar poliomyelitis. **JAMA** 1943; 123:1096-7.
25. Lassen HCA. Preliminary report on 1952 epidemic of poliomyelitis in Copenhagen with special reference to treatment of acute respiratory insufficiency. **Lancet** 1953; 1:37-43.
26. Safar P, Penninckx J. Cricothyroid membrane puncture with a special cannula. **Anesthesiology** 1967; 28:943-8.
27. Burkey B, Esclamado R, Morganroth M. The role of cricothyroidotomy in airway management. **Clin Chest Med** 1991; 12:561-71.
28. Skaggs JA, Cogbill CL. Tracheostomy: Management, mortality, complications. **Am Surg** 1969; 35:393-6.
29. Friedman Y, Franklin C. The technique of percutaneous tracheostomy. **J Crit Illness** 1993; 8:289-97.
30. Melker JS, Gabrielli A. Melker cricothyrotomy kit: an alternative to the surgical technique. **Ann Otol Rhinol Laryngol** 2005; 114:525-8.
31. Keane MF, Brinsfield KH, Dyer KS, Roy S, White D. A laboratory comparison of emergency percutaneous and surgical cricothyrotomy by pre-hospital personnel. **Prehosp Emerg Care** 2004; 8:424-6.
32. Johnson DR, Dunlap A, McFeeley P, Gaffney J, Busick B. Cricothyrotomy performed by pre-hospital personnel: a comparison of two techniques in a human cadaver model. **Am J Emerg Med** 1993; 11:207-9.
33. Schaumann N, Lorenz V, Schellongowski P, Staudinger T, Locker GJ, Burgmann H, et al. Evaluation of Seldinger technique emergency cricothyroidotomy versus standard surgical cricothyroidotomy in 200 cadavers. **Anesthesiology** 2005; 102:7-11.
34. Fisher JA. A last ditch airway. **Can Anaesth Soc J** 1979; 26:225-30.
35. Dob DP, McLure HA, Soni N. Failed intubation and emergency percutaneous tracheostomy. **Anaesthesia** 1998; 53: 72-74.
36. Wong DT, Lai K, Chung FF, Ho RY. Cannot intubate-cannot ventilate and difficult intubation strategies: results of a Canadian national survey. **Anesth Analg** 2005; 100:1439-46.
37. Ciaglia P, Brady C, Graniero KD. Emergency percutaneous dilatational cricothyroidostomy: use of modified nasal speculum. **Am J Emerg Med** 1992; 10:152-5.
38. Metterlein T, Frommer M, Ginzkey C, Becher J, Schuster F, Roewer N, et al. A randomized trial comparing two cuffed emergency cricothyrotomy devices using a wire-guided and a catheter-over-needle technique. **J Emerg Med** 2011; 41:326-32.
39. Aneeshkumar MK, Jones TM, Birchall MA. A new indicator-guided percutaneous emergency cricothyrotomy device: in vivo study in man. **Eur Arch Otorhinolaryngol** 2009; 266:105-9.